

# Ganglioneuroma of Deep Face- A case report

Bouvier Francis Valere D'sa<sup>1</sup> , Sohaila Fatima<sup>2\*</sup> , Nazima Haider<sup>2</sup>

1.Department of Laboratory Medicine, Aseer Central Hospital, Abha , KSA

2.Department of Pathology, King Khalid University, Abha , KSA

## Abstract

Ganglioneuroma is a rare tumor of neural crest origin and is included under category of peripheral neuroblastic tumors .It is a benign tumor mainly found in posterior mediastinum and retroperitoneum. Here we present a case of 12 year old boy who was diagnosed as ganglioneuroma involving deep facial structures - infratemporal fossa extending to adjacent structures.

**Keywords** : Ganglioneuroma ,deep face, infratemporal fossa

## Introduction

Ganglioneuroma (GN) is an uncommon benign entity of the peripheral neuroblastic tumors (PNTs) that occur commonly in childhood [1].It arises from cells found in the sympathetic ganglia and the adrenal medulla .It is fully differentiated tumor that contains no immature elements. It is rare compared with other benign neural tumors such as schwannoma and neurofibroma but outnumbers neuroblastomas (NB) along the sympathetic axis by about 3 to 1. It is most often located in the posterior mediastinum, retroperitoneum and uncommonly in adrenal proper [2] .We present a 12 year old boy who presented with prominence of left cheek and proptosis of left eye and was diagnosed as GN of infratemporal fossa extending to adjacent structures.

## Case Report

A 12 year old boy presented with prominence of left cheek and bulging of left eye of 3 months duration without difficulty in vision. On physical examination he was able to fix and follow in both eyes with 2-3 mm of left eye proptosis but full extra ocular movement. On biomicroscopy normal anterior segment examination with regular and reactive pupil was seen. His fundus and optic nerve examination were unremarkable.Hematological and biochemical investigations were normal.Vanillyl mandelic acid (VMA): 4 milligrams /24 hours. Computerised tomography (CT) of brain , orbit , paranasal sinus and face and magnetic resonance imaging (MRI) revealed soft tissue mass involving infratemporal fossa extending to pterygopalatine fossa via pterygomaxillary fissure , sphenopalatine foramen and to left orbit leading to proptosis . Intracranially it extended to apical part of temporal lobe . Opacification of left maxillary sinus and ethmoid air cells was noted. CT scan of chest, abdomen and pelvis were normal. Surgical resection of tumor was performed. On gross examination the excised mass measured 14 x 12x 10 mm. Histopathological examination revealed scattered nests of mature ganglion cells with distinct cell borders , single eccentric nucleus , prominent nucleolus , eosinophilic cytoplasm admixed with fascicles of Schwann cells. Stroma was densely collagenised with no involvement of bony trabeculae . There were no features of necrosis , atypia or mitosis(Figure 2). Immunohistochemical staining was positive for S-100

in ganglia and Schwann cells (Figure 3) and a diagnosis of GN was made . Postoperatively the patient had **an uneventful course.**

## Discussion

GN is a rare tumor of neural crest origin and comes under category of the PNTs which also includes the malignant histotypes NB and ganglioneuroblastoma (GNB) nodular and stroma-rich intermixed[1]. These tumor categories represent a spectrum of maturation from the most primitive form, NB to the most mature form, GN[3]. GNB was defined as a transitional tumor of sympathetic cell origin that contained malignant neuroblastomatous and benign ganglioneuromatous element by Robertson in 1915 [4]. There was no clear delineation between NB and GNB and between GNB and GN. The International Neuroblastoma Pathology Classification (INPC) established in 1999 defined GN as a schwannian stroma-dominant tumor predominantly composed of ganglioneuromatous stroma with a minor component of scattered collections of differentiating neuroblasts and/or maturing or mature ganglion cells. GNB was characterized by well-defined microscopic nests of neuroblastic cells in various stages of differentiation, intermixed or randomly distributed in a ganglioneuromatous tissue in a background of abundant neuropil[1]. A revision in 2003 proposed four tumor categories in two distinct prognostic groups; Favorable Histology (FH) and Unfavorable Histology (UH) [5,6]. The INPC was the first to define the tumor categories using histologic indicators of both grade of neuroblastic differentiation and Schwannian stromal development by accommodating the system developed by Shimada[7].GN are always classified into the FH group. GN may evolve as a mature tumor from the very beginning or by spontaneous or treatment-induced differentiating NB or GNB. Intact 1p chromosomes are important for self-limiting behavior of NB.[8] Metabolic activity metaiodobenzylguanidine (mIBG) uptake, Homovanillic acid (HVA) and VMA excretion in a substantial fraction of patients with histologically proven GN, the higher age at diagnosis, and higher percentage of immature GNs suggest that most of the GN de facto evolved through differentiating NB. It remains unclear which NB had the biologic potential to differentiate to GN, but it should be supposed that only NB exhibiting intact chromosomes 1, lack of MYCN amplification, and near-triploid DNA values can mature into secondary benign ganglioneuromatous tumors. The difference in distribution of NB and GN support the idea that most GN develop de novo rather than by way of maturation in a preexisting NB [9].

GN is more common in adolescents and young adults whereas NB and GNB mostly occur in infants and children[10].In a study by Georger and colleagues of 49 patients with this tumor, the median age at diagnosis was 79 months (compared to 16 months for patients with NB). Males and females were equally affected **with 41.5% arising** in the thoracic cavity, 37.5% in the abdomen outside of the adrenal gland **and 21%** within the adrenal parenchyma [9]. GN may also be found at other sites including the skin, retro- or parapharynx, the para-testicular region and gastrointestinal tract (GIT). In the GIT polypoid GN have been reported in association with several inherited diseases including Cowden syndrome, tuberous sclerosis and juvenile polyposis. Ganglioneuromatous polyposis has been described in patients with type I neurofibromatosis and multiple endocrine neoplasia type IIb [2].**There are cases involving head and neck but we did not come across any case involving infratemporal fossa.** Our patient presented with GN involving infratemporal fossa extending to pterygopalatine fossa via pterygomaxillary fissure ,sphenopalatine foramen and to left orbit which is a very rare location for this tumor. The infratemporal fossa is a complex space that lies posterolateral to the maxillary sinus and many important nerves and vessels traverse it.These tumors usually come to clinical attention either incidentally or due to local mass

effect on nerves[11]. GN may present with metabolic activity such as increased secretion of catecholamines and/or mIBG uptake. There are no specific diagnostic signs or symptoms discriminating GN and NB . Therefore GN requires tissue investigation for diagnosis.Grossly the GN is a well-circumscribed tumor with a fibrous capsule. Histologically it consists of bundles of Schwann cells and mature ganglion cells [2]. **HPE in our patient revealed scattered nests of mature ganglion cells admixed with fascicles of Schwann cells and densely collagenised stroma.**On CT imaging, these tumors may be homogeneous or heterogeneous masses with low to intermediate attenuation . Calcification seen in 20% of cases is usually punctate as opposed to the coarse pattern seen in its malignant counterparts. Following contrast administration, the tumors demonstrate mild to moderate enhancement .On MR imaging GN appear as homogeneous mass with low and intermediate signal intensity on T1-weighted images [12]. **In our patient MR signals were mainly of low intensity on T1 weighted images and of high intensity on T2 weighted images .Radiologically the differentials were lymphoma , Langerhans cell histiocytosis and sarcoma.** Rare GN undergo malignant transformation and most commonly the malignant component resembles a malignant peripheral nerve sheath tumor [2].

Treatment for symptomatic extracranial GN consists of complete surgical excision, with radiological surveillance for local recurrence .In a study of 28 patients with complete resection and 12 with clinical tumor residuals no tumor progression was noted after treatment was completed [9].

### **Conclusion**

GN are rare indolent benign neuroblastic tumors which are diagnosed histologically. Thorough sampling of the tumor is required to look for neuroblastic component which will **modify** the diagnosis. They have excellent prognosis **after surgical resection..**

### **Consent Disclaimer:**

As per international standard or university standard, patient's consent has been collected and preserved by the authors.

### **References**

- 1.Shimada H, Ambros IM, Dehner LP, Hata J, Joshi VV, Roald B. Terminology and morphologic criteria of neuroblastic tumors: recommendations by the International Neuroblastoma Pathology Committee. *Cancer*.1999; 86:349–63. [PubMed: 10421272]
- 2.Goldblum, John R; Folpe, Andrew L; Weiss, Sharon W; Enzinger, Franz M. *Soft tissue tumors*; Weiss, Sharon W. Enzinger and Weiss's soft tissue tumors.6th ed. Philadelphia, PA :Saunders/ Elsevier, c2014.NLM ID: 101604149
- 3.Okamatsu C, London WB, Naranjo A, Hogarty MD, Gastier-Foster JM, Look AT, *et al*. Clinicopathological characteristics of ganglioneuroma and ganglioneuroblastoma: a report from the CCG and COG. *Pediatr Blood Cancer* 2009;53:563–69.
4. Robertson HE. Das GanglioneuroblastomeinbesonedererTypusim System der Neurome.Virchows Arch [PatholAnat]. 1915; 63:147–168. 14.

5. Shimada H, Ambros IM, Dehner LP, et al. The International Neuroblastoma Pathology Classification (the Shimada system). *Cancer*.1999; 86:364–72. [PubMed: 10421273]
6. Peuchmar M, d'Amore ESG, Joshi VV, et al. Revision of the International Neuroblastoma Pathology Classification. Confirmation of Favorable and Unfavorable Prognostic Subsets in Ganglioneuroblastoma. *Nodular Cancer*.2003; 98:2274–81.
7. Shimada H, Chatten J, Newton WA, et al. Histopathologic prognostic factors in neuroblastic tumors: definition of subtypes of ganglioneuroblastoma and age-linked classification of neuroblastomas. *J Natl Cancer Inst*. 1984; 73:405–416. [PubMed: 6589432] .
8. Ambros IM, Zellner A, Roald B, Amann G, Ladenstein R, Printz D, et al. Role of ploidy, chromosome 1p, and schwann cells in the maturation of neuroblastoma. *N Engl J Med* 1996;334:1505–11.
9. Georger B, Hero B, Harms D, et al. Metabolic activity and clinical features of primary ganglioneuromas. *Cancer* 2001; 91:1905.
10. Tungenwar PN, Bhandarwar AH, Gandhi S, Binayke R, Agarwal S, Pai A. Adrenal ganglioneuroma: A rare case presentation. *Int J Case Rep Images* 2016;7(8):519–23.
11. Lonergan GJ, Schwab CM, Suarez ES, Carlson CL. Neuroblastoma, ganglioneuroblastoma, and ganglioneuroma: radiologic-pathologic correlation. *Radiographics* 2002;22: 911–34.
12. Ichikawa T, Ohtomo K, Araki T, et al. Ganglioneuroma: computed tomography and magnetic resonance features. *Br J Radiol* 1996;69:114 –21.

**Figure Legends**

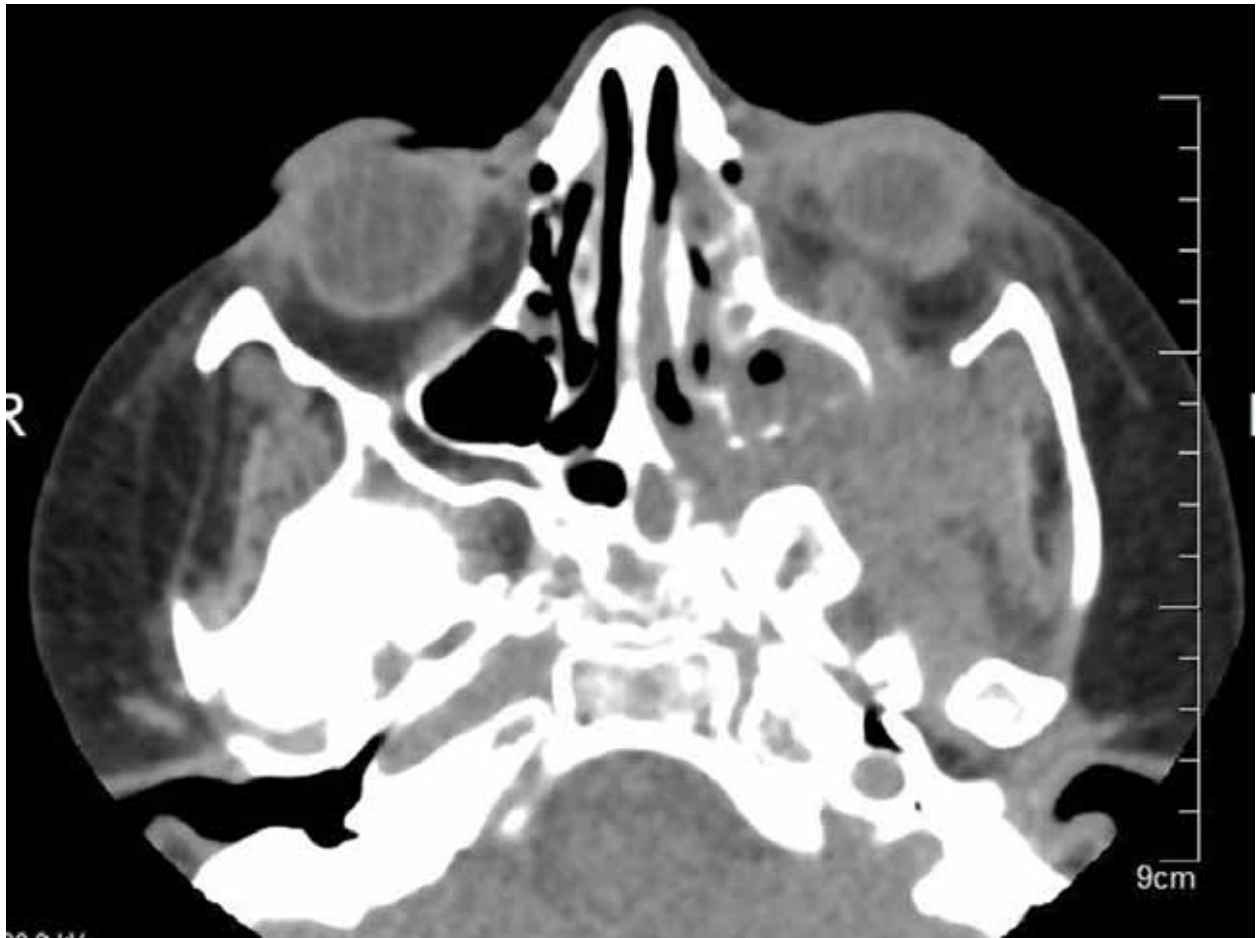

Figure 1. CT scan image shows a soft tissue mass in the left infratemporal fossa extending to pterygopalatine fossa via pterygomaxillary fissure, sphenopalatine foramen and to left orbit.

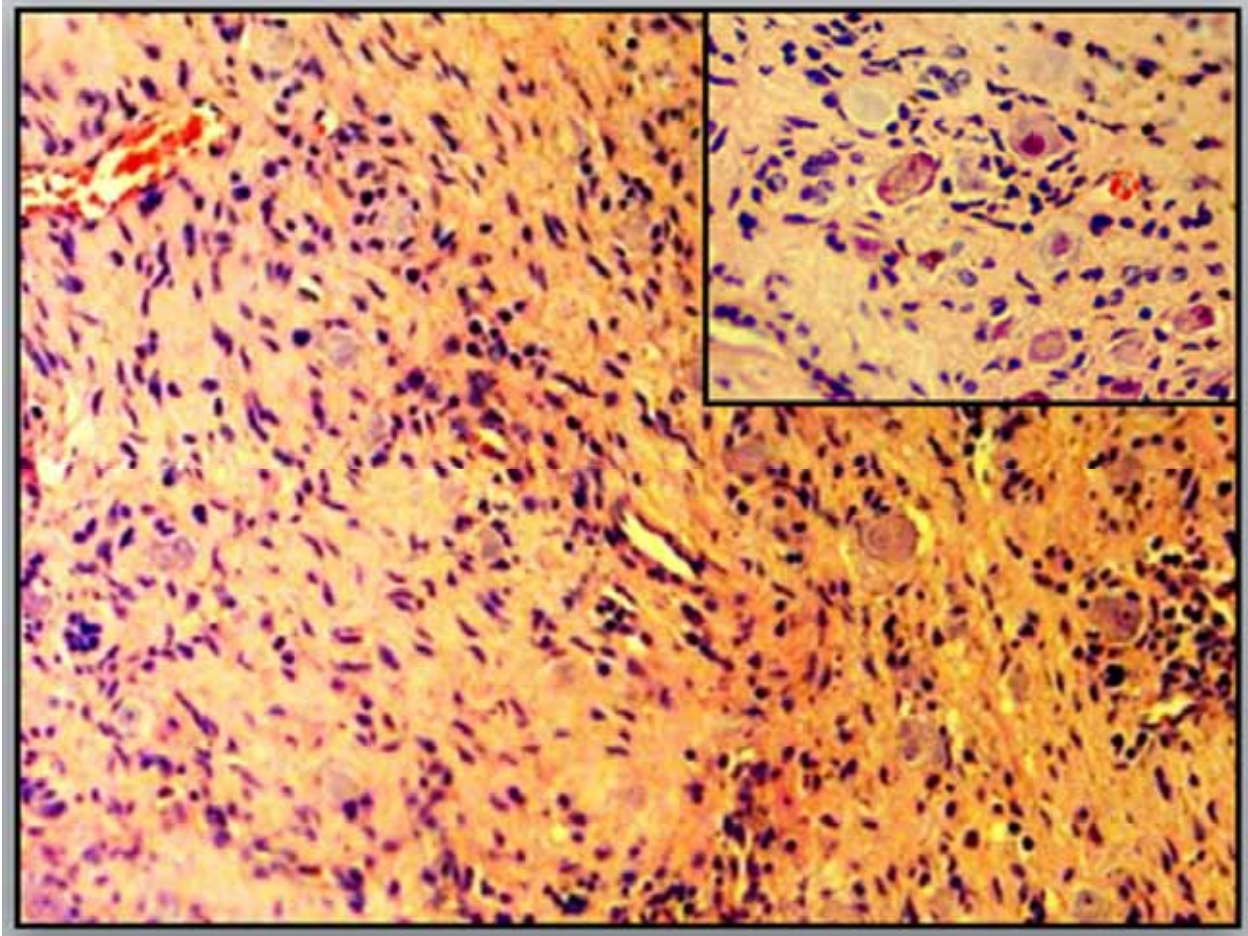


Figure 2. Scattered nests of mature ganglion cells admixed with fascicles of spindle shaped Schwann cells and densely collagenised stroma. Mature ganglion cells with distinct cell borders, single eccentric nucleus, prominent nucleolus and eosinophilic cytoplasm seen (Hematoxylin and Eosin- 20x, Inset-40x)

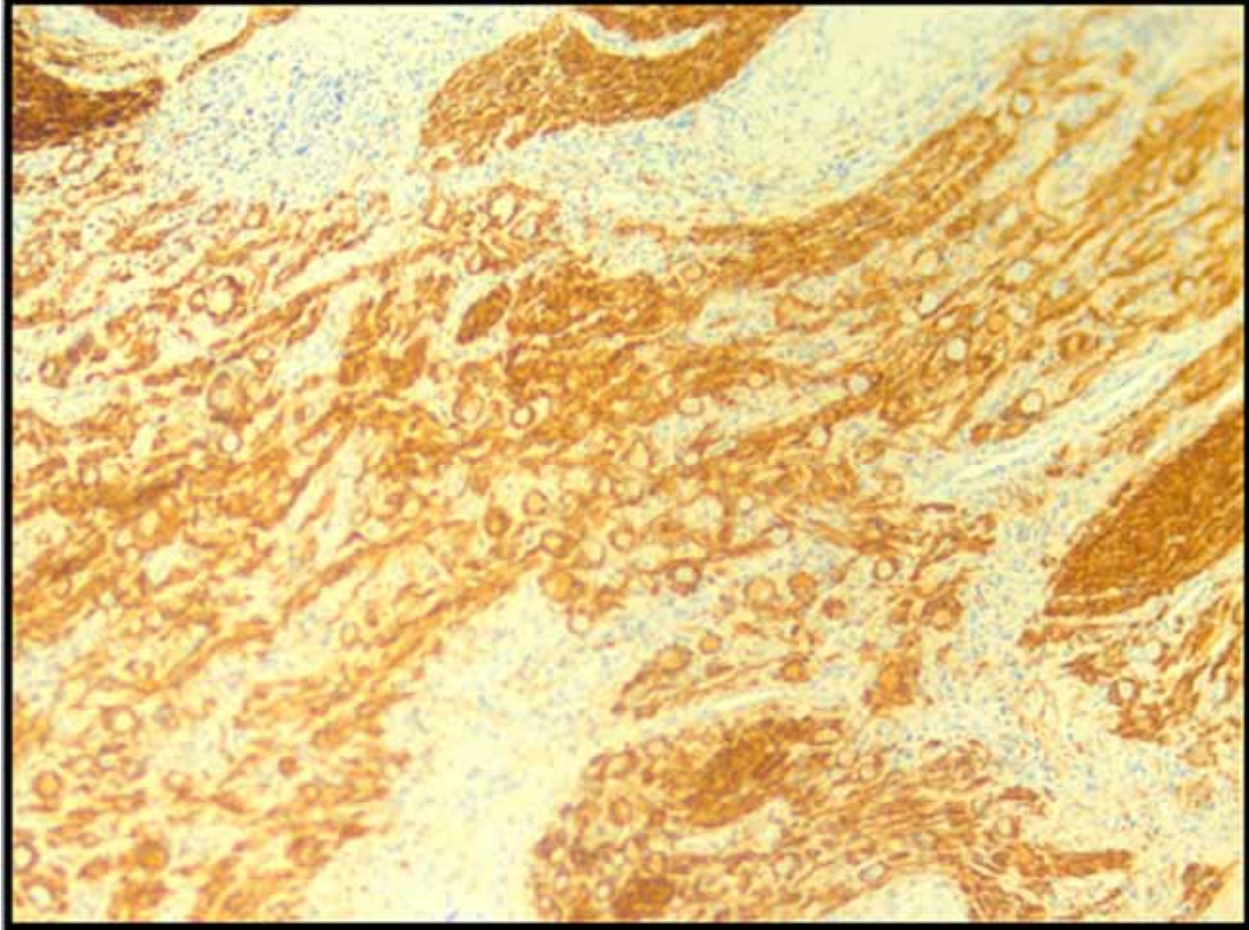


Figure 3 :Immunohistochemical study showing S100 positivity in ganglia and schwann cells(S100x20x)