

CORNUAL TWIN ECTOPIC PREGNANCY: A CASE REPORT

Oriji Vaduneme Kingsley (MBBS, FWACS)

Department of Obstetrics and Gynaecology, University of Port Harcourt Teaching Hospital, Port Harcourt.

Nyeche Solomon (MBBS, FWACS)

Department of Obstetrics and Gynaecology, University of Port Harcourt Teaching Hospital, Port Harcourt.

Ibe Vitalis (MBBS, FWACS)

Department of Obstetrics and Gynaecology, University of Port Harcourt Teaching Hospital, Port Harcourt.

Correspondence: Dr. V. K Oriji

Email- yadoriji@yahoo.com

Phone: 2348033133037

ABSTRACT:

A 22 years old female, G1P0E(ectopic) 1, who presented with ten hours history of sudden onset of lower abdominal pains, which later became generalized and progressive, abdominal distension, dizziness and weakness after thirteen weeks amenorrhea. She had a previous history of left partial salpingectomy for ruptured ectopic gestation. She was treated with a repeat laparotomy and right-sided wedge resection for the index ruptured cornual pregnancy. Two fetuses and the placenta were removed from the peritoneal cavity. She was discharged from the hospital 5 days later in stable clinical condition.

INTRODUCTION

Ectopic pregnancy is an important direct cause of maternal death. Cornual ectopic pregnancy is rare but about the most hazardous form of ectopic pregnancy. It accounts for 2-6% of all ectopic pregnancies with an incidence of 1 per 2500-5000 live births and the mortality is 6-7 times higher than in other ectopics.¹⁻³ It occurs when the fertilized egg implants in that part of the fallopian tube buried in the wall of the uterus. With the presence of myometrium around the sac, cornual pregnancies are more difficult to diagnose, as they appear to be in the uterus on ultrasonography. They tend to rupture later due to myometrial distension with potentially devastating haemorrhage when compared to other ectopics.¹ Cornual ectopic is rare but even rarer is a twin cornua ectopic that will present earlier with rupture and a worse haemorrhagic condition. We report an unusual case of a recurrent contralateral 13-weeks ruptured cornual twin ectopic pregnancy.

CASE REPORT

A 22-year old lady, G1P0E(ectopic)1, presented to the accident and emergency department of the University of Port Harcourt Teaching Hospital (UPTH) with a ten-hour history of sudden onset of lower abdominal pain, abdominal distension and weakness, dizziness and sudden collapse following a thirteen weeks amenorrhea. There was no history of trauma to the abdomen.

She attained menarche at 15 years. She has a regular monthly 4 days menses. She was not on any contraception even though she did not want the pregnancy. She had laparotomy and left salpingectomy for ruptured ectopic gestation 8 months prior to this event. She had no other significant past medical history. She is unmarried but resides with her fiancée who is a cab driver. She is an African with secondary education but unemployed. She has no family history of hypertension or diabetes mellitus. She takes alcohol occasionally but does not take tobacco or other addictive substances.

Physical examination at presentation showed an anxious lady, pale and sweaty. Her respiratory rate was 24 cycles per minute and her breath sounds were normal. Her pulse rate was 120 beats per minute, her blood pressure was 90/60 mmHg and her heart sounds were normal.

Her abdomen was distended with a midline sub-umbilical scar. There was generalized abdominal tenderness with guarding and positive fluid thrill.

The vulva, vagina and the cervix appeared normal on pelvic examination. The uterus was difficult to delineate due to tenderness. The fornices were bulging and tender.

The diagnosis of ruptured ectopic gestation was made. Her pelvic ultrasonography showed an enlarged empty uterus with marked free peritoneal fluid. Her pregnancy test was positive. Her packed cell volume was 20% and two units of compatible blood was made available for use during surgery. She and her partner were informed of the findings and diagnosis. The need for an emergency repeat laparotomy was communicated to them and they gave consent for the surgery. Prior to surgery she received 2 liters of normal saline, 30 mg of pentazocine and 25 mg of promethazine.

Findings at laparotomy were 1.5 liters of haemoperitoneum, ruptured right cornual pregnancy, bilateral normal ovaries and absent right fallopian tube. Two male fetuses and the placenta were found in the pelvic cavity. A right-sided wedge resection of her uterine cornua, excising the site of the ectopic pregnancy was carried out. The resected portion of the uterus was apposed together with vicryl 1 suture material and haemorrhage controlled. The abdominal cavity was closed with vicryl 2 to the rectus sheath and nylon 2/0 to skin. She was transfused with two units of blood intra-operatively. She was discharged home 5 days later in a stable

clinical condition after a discussion on the event and outcome of the surgery. Her follow up six weeks later showed she was in good health. She was referred to a fertility clinic for invitro- fertilization and embryo transfer in a future date.

DISCUSSION

As demonstrated in this case, a previous history of ectopic pregnancy with salpingectomy remains a strong risk factor for repeat ectopic pregnancy. Other risk factors include pelvic inflammatory disease, congenital defects of the fallopian tubes, history of infertility, assisted reproductive treatment (ART), use of intra-uterine contraceptive device and the exposure to diethyl stilbesterol in-utero, history of previous ectopic pregnancy.^{3,4,5}

The history of sudden onset of lower abdominal pain, progressive weakness and abdominal swelling following 13 weeks amenorrhea in this patient with previous ectopic pregnancy aroused a clinical suspicion of another ruptured ectopic pregnancy. **Her presentation** from the referral hospital in haemodynamic shock with haemoperitonium left no other option than prompt resuscitation with intravenous fluids and emergency laparotomy where the definitive diagnosis was made and the haemorrhage arrested. **She had a left tubal pregnancy** where partial salpingectomy was done about eight months ago. **Previous ectopic pregnancy is a recognized risk factor for recurrent ectopic pregnancy. Therefore it is recommended that those with previous ectopic pregnancy be screened for a repeat ectopic pregnancy in early pregnancy using ultrasonography and quantitative beta hCG.** The diagnosis of ectopic pregnancy using USG criteria include an empty uterus, a gestational sac separate from the uterine cavity, a myometrial thinning of less than 5mm around the gestational sac, an interstitial line sign, which is an echogenic line from the endometrial cavity to the corner which is next to the gestational mass is seen⁵. Also, an early ultrasound diagnosis of cornual ectopic may be possible with the identification of the interstitial line, this however does not entirely eliminate the confusion at ultrasonography between a normal intrauterine pregnancy and a cornual pregnancy.⁵⁻⁸ Also, the concept of the discriminatory zone using serum levels of human chorionic gonadotropin⁹ to identify an ectopic pregnancy

introduced by Kader and his Colleagues in 1987 may be misleading in cornual ectopic pregnancies especially in this case with twin fetuses.

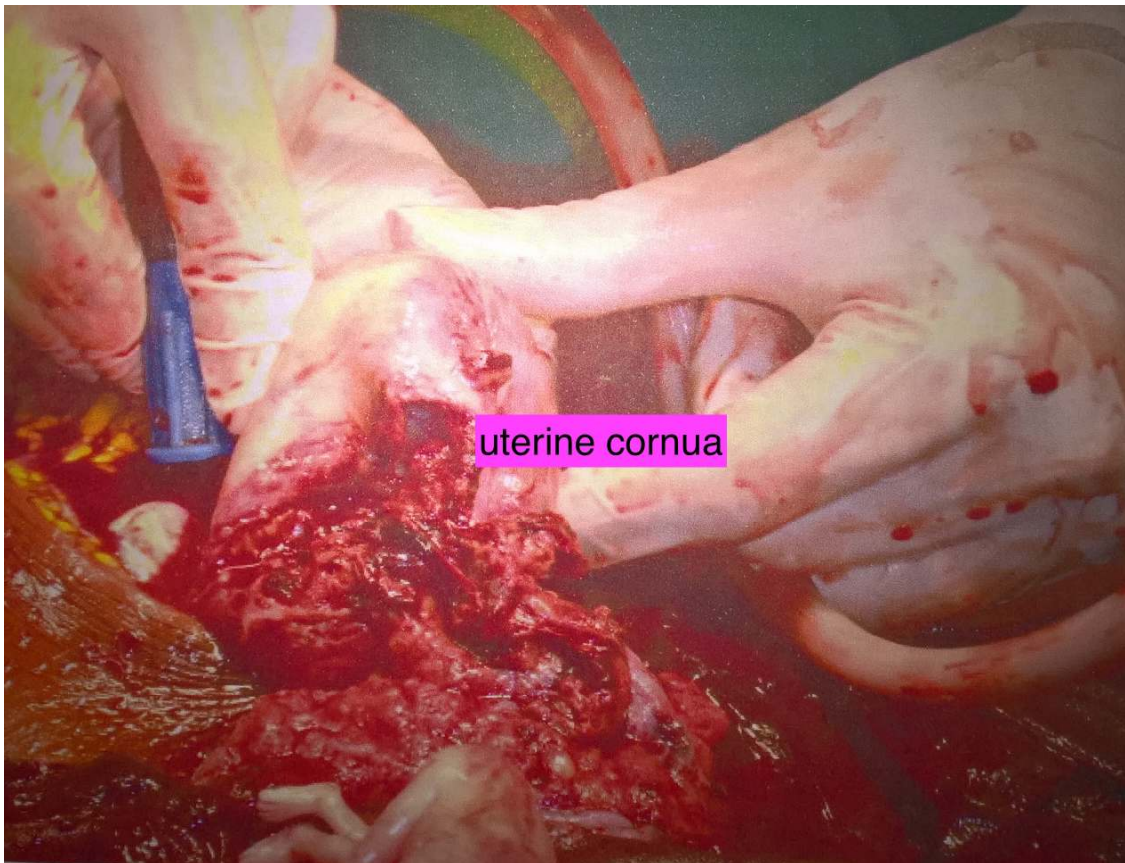
Cornual pregnancy with its closeness to both the uterine and **ovarian branches of the uterine arteries pose a high surgical risk with the potential for massive intra peritoneal bleeding when ruptured.**¹⁰ The patient was treated with cornual wedge resection **of the ectopic site**, which controlled the bleeding. Cornual wedge resection or hysterectomy in cases of uncontrollable haemorrhage has been the traditional treatment options for a ruptured cornual ectopic gestation. An ipsilateral uterine artery ligation before cornual resection and repair has been recommended by some authors to reduce haemorrhage in ruptured cornual ectopic pregnancy.^{8,11} Minimally invasive techniques like laparoscopic cornual resection, cornuostomy, salpingostomy, salpingectomy, uterine artery embolization, combined hysteroscopic and laparoscopic or ultrasound guided techniques have all been used in selected cases.^{1,11-13} Medical management with intramuscular methotrexate adopting strict criteria for medical management of ectopic pregnancy has been employed in some conservative management of cornual ectopic pregnancy with good results.^{14,15} These management options however, are not popular in our settings now for two main reasons. The first is that majority of our patients present late in haemodynamic shock from catastrophic haemorrhage from the ruptured ectopic pregnancy and the other is the lack of equipment and trained manpower for minimally invasive surgery.

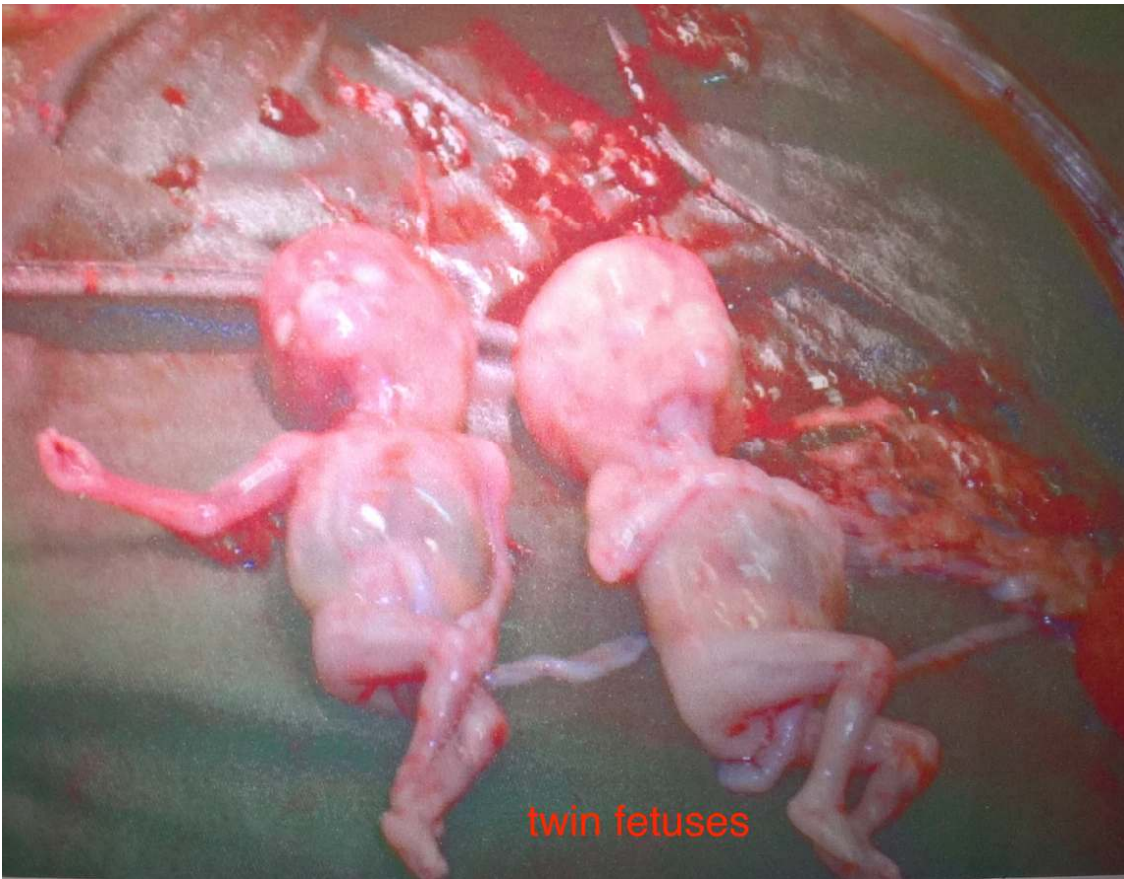There is the possibility of a future pregnancy in this patient with **assisted reproductive techniques such as IVF-ET**. However, effort must be made to rule out another ectopic pregnancy. Caesarean delivery is recommended if she does conceive an intrauterine pregnancy due to concern for uterine rupture secondary to weakness in the myometrium at the site of the last ectopic pregnancy.

CONCLUSION:

Cornual pregnancy is a rare and hazardous variety of ectopic pregnancy. A cornual twin ectopic is even most rare, as just a single case of cornual twin ectopic pregnancy has been reported in literature. As seen in this case, the diagnosis and

treatment are often challenging and commonly constitute medical emergencies. The serious consequences of cornual ectopic are the catastrophic haemorrhage and even maternal death when it ruptures.





Reference:

1. Fubara DS, Ikimalo J, John CT. Pathology of maternal deaths in Rivers State: a ten year review in a referral hospital. *Nigerian Postgraduate Medical Journal* 2007; 14(3): 256-260
2. Tuland T, Al-Jaroudi D. interstitial pregnancy: results generated from the society of reproductive surgeons registry. *Obstetrics And Gynaecology* 2004; 103: 47-50
3. Orphir E, Singer-jordan J. Uterine artery embolization for the management of interstitial twin ectopic pregnancy: case report. *Human reproduction* 2004;19(8): 1774-7
4. Anorlu RI, Oluwole A, Abudu OO, Adebajo S. Risk factors for ectopic pregnancy in Lagos Nigeria. *Acta Obstetrica et Gynaecologica Scandenevica* 2005; 84(2): 184
5. Surekha SM, Chamaraja T, Nabakisore SN, Bimolchandra SN, Neeraja TS. A Ruptured Left Cornual Pregnancy: A Case Report. *Journal of Clin Diagnostic Research* 2013(7) 1455-1456
6. Gaber-Patel K, Smith MD. Thirteen week corneal ectopic pregnancy: Am J Emerg. Med 2009; 27(7):900.el-2
7. Takei T, Matsucka S, Ashitani N, Nakihara N. Ruptured corneal ectopic pregnancy. case report. *Clinical Exp Obstet Gynaecol* 2009; 36(2): 130-2
8. Kader N, DeYore G, Romeo R. Discriminatory hcg zone: its use in the sonographic evaluation for ectopic pregnancy. *Obstet Gynecol* 1981; 58: 156-61
9. Khawaja N, Walsh T, Gill B. Uterine artery ligation for management of ruptured cornual ectopic pregnancy. *Eur J Obstet Gynaecol reprod boil* 2005; 118: 269.
10. Gimbizis GF, Tsalikis T, Mikos T. case report repor: Laparoscopic treatment of ruptured interstitial pregnancy. *Reprod Biomed Online* 2004; 9:447-51
11. Pal B, Akinfenwa O, Kevin H, Hysteroscopic management of cornual ectopic pregnancy: *BJOG* 2003; 100: 879-80

12. Morgan M, Aziz Mikhail, Henein M, Atalia R. ultrasound guided treatment of cornual ectopic. Eur J Obstet Gynaecol reprod Biol 2009; 143(2); 126
13. Jermy K, Thomas J, Doo A, Bourne T. The conservative management of interstitial pregnancy. BJOG 2004; (111): 111:1283-8
14. Stoval TG, Ling FW. Single dose methotrexate: an expanded clinical trail. Am J obstet Gynaecol 1993; 168:1759-65
15. Hussein W, Mamta M, Mohammad A, Mostafa I. Interstitial Ectopic Pregnancy: Conservative Surgical Management. Journal of Society of Laparoendoscopic Surgeons 2014. (18)2 197-203