

Case study

Primary breast lymphoma with delay response to treatment: a case report

Abstract

Primary breast lymphoma is a rare disease and representing 0.04 – 0.5 % of all malignant female breast tumor. Patient usually present to palpable mass in the breast without any evidence of lymphoma in the other organs. imaging finding is non-specific .histopathologic exam is only confirmed with histopathologic examination. We report a 57 years old women presented with a palpable mass in the left breast from 2month ago .Ultrasonography and elastography revealed a 3 cm hard lobulated mass. The mass was lobulated with partially obscured border in mammogram without micro calcification histopathologic and immunohistochemical finding confirmed the diagnosis. Chemotherapy was initiated with RCHOP regiment however after two cycle of chemotherapy there isn't any obvious response to treatment .repeat biopsy revealed some edematous changes within tumoral mass resulted in false growth of tumor however after 8 cycle of chemotherapy the mass regressed. Early and accurate diagnosis and complete course of treatment is crucial for appropriate treatment strategies and avoid unnecessary mastectomy in management of primary breast lymphoma.

Keywords: Primary breast lymphoma, Mammography, Chemotherapy

Introduction

Primary breast lymphoma is first described by Gross in 1880 (1) and according to very little lymphoid tissue in breast PBL is a rare disease and representing 0.04–0.5 % of all malignant female breast tumor (2) and defined as follow: lymphoma first manifested in the breast without history of lymphoma elsewhere. Usual symptom is painless lump in breast. Skin edema, nipple retraction, fever weight loss is less frequent (3) imaging finding is nonspecific. in the mammography the lesion present as circumscribed mass without any calcification .on the Ultrasound the mass is usually hypoechoic (4) Diffuse B cell lymphoma is the most common subtype accounts for 40- 70% of all breast lymphoma (5,6). The diagnostic approach is including imaging investigation and immunohistochemical biomarkers evaluation (7). The diagnosis is only established with histological examination. Accurate and early diagnosis is very important to avoid the harmful surgical intervention and appropriate medical treatment and the best outcomes.

Case report:

A 57 years old women presented with a palpable mass in the upper outer quadrant of left breast from 2 month ago measured about 3 x 2 cm on physical examination the mass was palpable, firm and non-mobile with bulging on the skin. There isn't any evidence of nipple retraction or bloody discharge. Right breast was normal. Biochemical blood analysis was unremarkable. Screening mammography 6 month ago was normal without obvious mass or micro calcification however recent imaging investigation including ultrasonography and mammography confirmed the presence of mass lesion. Ultrasound revealed a large lobulated mass (30 x 18 mm) with highly echogenic border and pathologic posterior acoustic shadow. On the elastography the lesion was hard (elasticity: 125 kPa) axillary lymph node was detect. The recent mammography showed partially obscured lobulated mass without obvious

speculation and micro calcification in the setting of dense breast suggestive of breast carcinoma.

Core needle biopsy under local anesthesia was performed. histopathologic investigation confirmed the diagnosis of diffuse large B cell lymphoma thoracic and abdominopelvic computed tomography (CT) and whole body scan was negative for infiltration of disease and showed the tumor confined to the breast alone. So diagnosis was compatible with primary breast lymphoma after the diagnosis chemotherapy was initiated with RCHOP regimen (rituximab, cyclophosphamide, doxorubicin, vincristine, and prednisone) however after two cycle of chemotherapy. According to progressive lump growth breast MRI as complementary imaging investigation was performed. A 39 x 36 x 20 mm micro lobulated avidly enhancing mass in the outer to central part of left breast was well demonstrated on MRI imaging.

Repeat histologic investigation was performed and pathologic and immunohistochemical finding confirmed the diagnosis the immunohistochemically studies revealed the tumor cell was (+) for CD45, CD20, Ki67, BCL2 and BCL6 and (-) for ER and PR and CD10.

However there was severe edematous changes within the tumor cell which resulted in false growth of tumor mass The patient followed with another 6 cycle of R CHOP regimen and somewhat regression was seen Finally response to treatment was assessed by follow up MRI of breast Considerable regression in the size of tumor was seen and the patient is in control after 12 month (Figure1-6).

Discussion

Primary breast lymphoma is rare entity according to increasing frequency of primary breast lymphoma (8). The disorder should be considered as a differential diagnosis of breast malignant disease. Mammography reveal a mass with different size without

Microcalcification as in our case. ultrasound confirm the presence of solid lobulated mass (9). However, there isn't any pathognomonic imaging finding (10).

According to clinical and imaging finding differentiation between breast lymphoma and breast carcinoma is difficult and definite diagnosis is mainly based on histopathological examination (11).

However imaging modalities and a useful method for monitoring of response to treatment. High grade lymphoma represent as diffuse breast enlargement however as in our case, Intermediate and low grade lymphoma present as nodular lesion (12). According to study of Domchek more than 90% of PBL presented as pain less palpable mass (13). However pain is seen in about 4–15 % of patient (9). In 26 original study 0-22% of patient have significant symptoms (14). The most common histologic type is diffuse B cell lymphoma (15). Diffuse large B cell subtype is Account's for 40–70 % of all breast lymphoma (5,6). Other histologic types are including MALT lymphoma and Burkitt's lymphoma (15%, 12.2% and 10.3% respectively) (4).

The median age in East Asian countries is lower than Western countries (45–53 years versus 62- 64 years respectively) (16). There is lack of update standard guideline for treatment of PBL 24 In the past surgery was the gold standard for PBL (17). However according to recent study role of surgery is limited only in the palliation of symptom in progressive disease and also in the diagnosis of disease. According to high mortality rate in patients undergoing mastectomy and axillary node dissection in a meta-analysis Jennings et al. Emphasized surgery has no benefit in the management of breast lymphoma only for diagnosis (4).

Ryan et al. showed there is increased risk of mortality in patient after surgery (6). Chemotherapy is the main treatment modality and preferred regime is RCHOP. (Rituximab, cyclophosphamide, doxorubicin, vincristine and prednisolone)

A few studies show that rituximab improve the response to treatment and eradication of lymphoma. According to Miller et al. in comparison with CHOP alone, use of rituximab with CHOP increase survival rate (18), however according to study of Hosein et al. there isn't any improvement on survival rate with rituximab (10). Role of radiotherapy in treatment of lymphoma is controversial. Radiation alone is not sufficient in controlling of disease 26 Radiotherapy as an adjuvant therapy increased local control of disease and decreased the recurrence rate 32-34.

According to study of Jeannerest-sozzi et al. the prognosis of PBL is better by combined Chemotherapy and radiotherapy. There is some noticeable point Tumor growth after one or two dose of chemotherapy is not mean nonresponse to treatment There is some edema in the tumor cell as we seen in the second biopsy lymphoma should be seen as rapid progressive mass as in our case there isn't any pathologic lesion in the screening of patient in close clinical exam and previous mammography and ultrasound 6 month ago.

Evaluation of response to treatment should be considered after complete of 8 cycles of appropriate medical treatment including chemotherapy and adjuvant radiotherapy after one or two cycle of chemotherapy there is evidence of edema within the lesion and the mass may be falsely growth however for localized disease radiotherapy following chemotherapy significantly decrease ipsilateral recurrence 28 radiation has an important role in the treatment of lymphoma and decrease of recurrence rate and could be considered in the patient treatment regimen however our patient is in control without radiation therapy.

Conclusion:

Definite diagnosis of primary breast lymphoma is only by histopathologic investigation and imaging finding is nonspecific. Delay response after two or three cycle is not important And after 8 cycle of chemotherapy (RCHOP) response to treatment should be evaluated.

Radiotherapy has a complementary role in management. Surgery does not have any role in management of PBL and early and definite diagnosis is important to avoid wrong diagnosis of carcinoma and unnecessary surgery.

Acknowledgement

We wish to thank our colleagues at the Clinical Research Development Center of Besat Hospital who provided us their insight and expertise that greatly assisted us in this research.

Disclaimer: - This manuscript was presented in the conference.

Conference name: - 4th World Congress on Medical Imaging and Clinical Research

Available link: - <https://www.omicsonline.org/conference-proceedings/2155-9937-C1-003-004.pdf>

September 03-04, 2018 | London, UK

Consent Disclaimer:

As per international standard or university standard written participant consent has been collected and preserved by the authors.

References:

1. Brogi E, Harris NL. Lymphomas of the breast: pathology and clinical behavior. In: Seminars in oncology. 1999. p. 357–64.
2. Ryan G, Martinelli G, Kuper-Hommel M, Tsang R, Pruneri G, Yuen K, et al. Primary diffuse large B-cell lymphoma of the breast: prognostic factors and outcomes of a study by the International Extranodal Lymphoma Study Group. Ann Oncol. Oxford University Press; 2007;19(2):233–41.
3. Heinzen RN, de Andrade FEM, Aguiar FN, de Oliveira FA, de Barros ACS. Primary breast lymphoma presenting as locally advanced breast cancer: a case report. Mastology (Impr). 2017;27(2):152–5.

4. Jennings WC, Baker RS, Murray SS, Howard CA, Parker DE, Peabody LF, et al. Primary breast lymphoma: the role of mastectomy and the importance of lymph node status. *Ann Surg.* Lippincott, Williams, and Wilkins; 2007;245(5):784.
5. Gupta D, Shidham V, Zemba-Palko V, Keshgegian A. Primary bilateral mucosa-associated lymphoid tissue lymphoma of the breast with atypical ductal hyperplasia and localized amyloidosis: a case report and review of the literature. *Arch Pathol Lab Med.* 2000;124(8):1233–6.
6. Ryan GF, Roos DR, Seymour JF. Primary non-Hodgkin's lymphoma of the breast: retrospective analysis of prognosis and patterns of failure in two Australian centers. *Clin Lymphoma Myeloma.* Elsevier; 2006;6(4):337–41.
7. Cavalli F, Stein H, Zucca E. Extranodal lymphomas: pathology and management. CRC Press; 2008.
8. Nisar U, Khan M, Nisar S, Khan S. Primary Breast Lymphoma with Unconventional Presentation: A Case Report. *J Leuk.* 2017;5(238):2.
9. Sabate JM, Gomez A, Torrubia S, Camins A, Roson N, De Las Heras P, et al. Lymphoma of the breast: clinical and radiologic features with pathologic correlation in 28 patients. *Breast J.* Wiley Online Library; 2002;8(5):294–304.
10. Hosein PJ, Maragulia JC, Salzberg MP, Press OW, Habermann TM, Vose JM, et al. A multicentre study of primary breast diffuse large B-cell lymphoma in the rituximab era. *Br J Haematol.* Wiley Online Library; 2014;165(3):358–63.
11. Yang H, Lang R, Fu L. Primary breast lymphoma (PBL): a literature review. *Clin Oncol Cancer Res.* Springer; 2011;8(3):128.

12. Surov A, Holzhausen HJ, Wienke A, Schmidt J, Thomssen C, Arnold D, et al. Primary and secondary breast lymphoma: prevalence, clinical signs and radiological features. *Br J Radiol. The British Institute of Radiology. 36 Portland Place, London, W1B 1AT;* 2012;85(1014):e195–205.
13. Domchek SM, Hecht JL, Fleming MD, Pinkus GS, Canellos GP. Lymphomas of the breast. *Cancer. Wiley Online Library;* 2002;94(1):6–13.
14. Jabbour G, El-Mabrok G, Al-Thani H, El-Menyar A, Al Hijji I, Napaki S. Primary breast lymphoma in a woman: a case report and review of the literature. *Am J Case Rep. International Scientific Literature, Inc.;* 2016;17:97.
15. Topalovski M, Crisan D, Mattson JC. Lymphoma of the breast: a clinicopathologic study of primary and secondary cases. *Arch Pathol Lab Med.* 1999;123(12):1208–18.
16. Cheah CY, Campbell BA, Seymour JF. Primary breast lymphoma. *Cancer Treat Rev. Elsevier;* 2014;40(8):900–8.
17. Farinha P, André S, Cabeçadas J, Soares J. High frequency of MALT lymphoma in a series of 14 cases of primary breast lymphoma. *Appl Immunohistochem Mol Morphol. LWW;* 2002;10(2):115–20.
18. Miller M, Danlberg S CJ. No Title. PBL, long term outcome and prognosis. *Leuk Lymph.* 2006;47(9).

Figure 1: ultrasonography revealed a large lobulated mass with highly echogenic border and posterior acoustic shadow

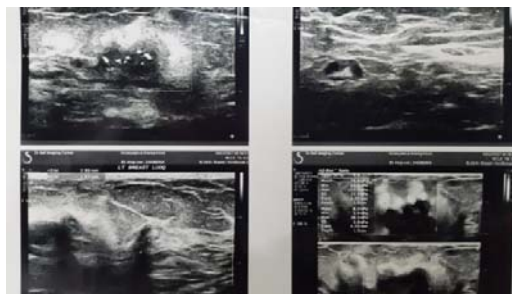

Figure 2; mammography showed a large lobulated and partially obscured mass in the left UOQ

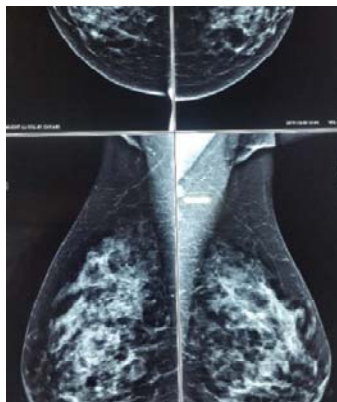


Figure 3: Whole body scan confirmed the lymphoma is limited to breast and there isn't any evidence of infiltrative disorder in the other organs

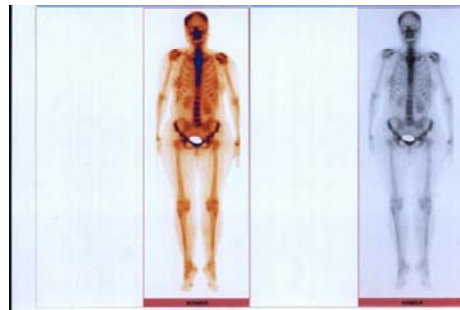


Figure 4: Contrast enhanced breast MRI with 3 dimensional reconstruction revealed lobulated enhancing mass in the left breast

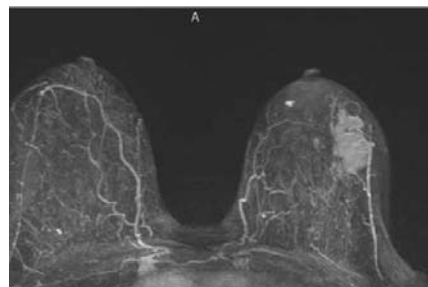


Figure 5: Histopathologic investigation compatible with diffuse large B cell lymphoma

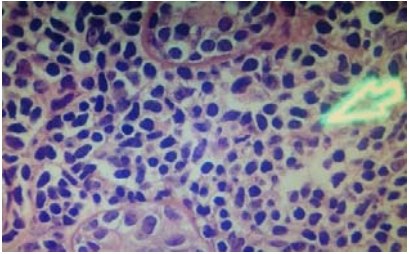


Figure 6: Breast MRI after 8 cycle of chemotherapy and adjuvant radiotherapy showing near total regression of left breast mass

