

Case study

Intraarticular Steroid Injection as a Treatment of Bertolotti's Syndrome: A Report of Three Cases

Abstract

Bertolotti's syndrome (BS) is defined as association between the congenital malformation lumbosacral transitional vertebra (LSTV) and low back pain (LBP). There are several treatments have been proposed including steroid injections, resections of the LSTV, laminectomy, and lumbar spinal fusion. We present a report of three young patients age from 25 to 30 with chronic low back pain extending to the left buttock and just above the ipsilateral sacroiliac joint. Radiographic investigation revealed an anomalous enlargement of the left transverse process of the fifth lumbar vertebra forming a pseudoarthrosis with the infradjacent ala of the sacrum. They are managed successfully with fluoroscopically guided intraarticular steroid injection with local anaesthetic over the transverse process-iliac articulation and after a follow-up of 6 months. This case report describes a simple non-surgical management for treating symptomatic lumbosacral junction pseudoarticulation that warrants better mode of treatment.

Keywords: *Bertolotti's Syndrome, Intraarticular steroid injection, Pseudoarticulation*

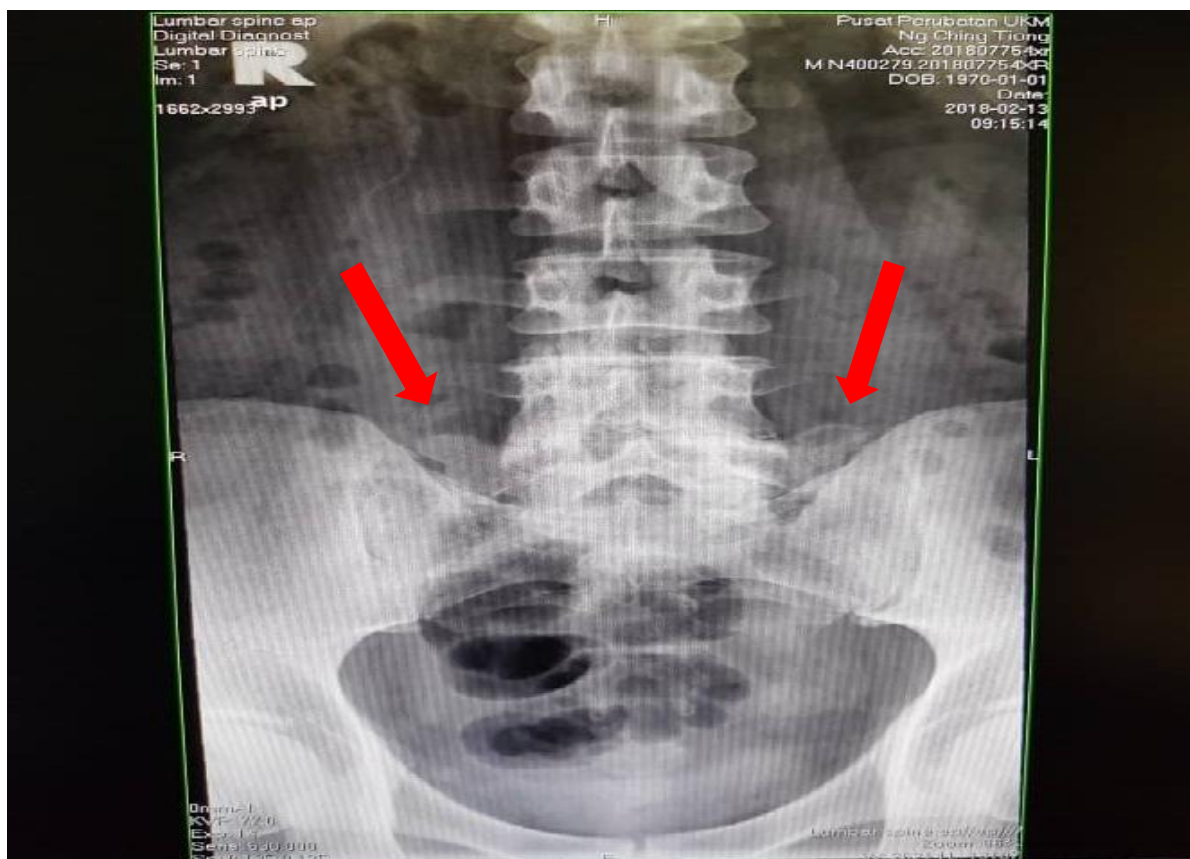Introduction

Bertolotti's syndrome (BS) was first described in 1917 by The syndrome was associated with axial low back pain (LBP) secondary to arthritic changes. The overall incidence of Bertolotti's syndrome has been reported to be between 4% to 8% in patients with low back pain¹. Recently, a very high incidence of 30% has been reported². To date, there has been no known effective non-surgical management options described¹. The pain generator in the syndrome has also not been identified because such an anatomical variation produces or not low back pain and/or sciatica is a subject of great debate². We present three case reports of patient with symptomatic BS managed successfully with fluoroscopically guided steroid injection of the transverse process-iliac articulation.

Case report

1) A 25 years old female was evaluated for chronic LBP associated with medial thigh cramping. She was treated with nonsteroidal antiinflammatory medications. The patient's pain was located in the low back, with radiation to the buttocks and anterolateral thighs. Provocative factors included forward flexion. The pain was not affected by prolonged sitting or standing. The quality of the pain was described as burning and sharp. The pain intensity on a Visual Analogue Scale (VAS) was 5/10. On physical examination the patient's bilateral lower extremities strength is full. Sensation was intact from L2 to S2. On palpation, there was focal tenderness along the base of the lumbosacral spine and near the posterior-superior iliac spine. Radiographs of the lumbar spine revealed an abnormal articulation between the L5

41 transverse process and the medial aspect of the ilium bilaterally, consistent with Bertolotti's
42 syndrome (Figure 1).



43

44 *Figure 1. Bilateral L5 transverse process articulation with medial aspect of the ilium*

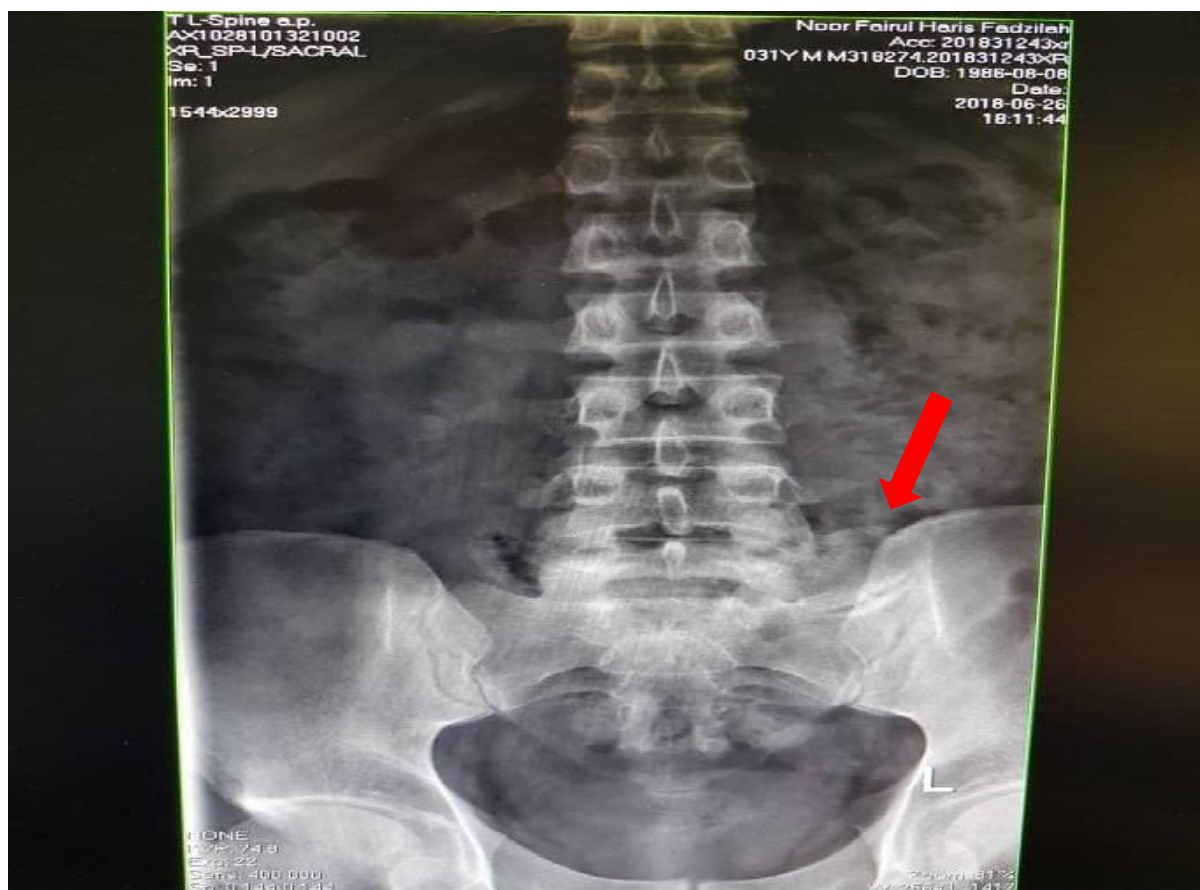
45

46 2) A 28 years old male presented for left LBP. He was on paracetamol for the last 3 weeks.

47 His symptoms began years before presentation after performing certain movements mainly
48 while bending forward on strenuous exercise. Physical examination demonstrated tenderness
49 over the lumbar spine and the area of the left sacrum, VAS 6/10. Laseque sign was negative

50 bilaterally. Reflexes, sensation and muscle power were normal on both lower limbs. The

51 radiographs demonstrated a typical lumbosacral transitional vertebra (LSTV), with an
52 extremely large left transverse process of the fifth lumbar vertebra, articulating with the ala of
53 sacrum (Figure 2).



54

55

56

Figure 2. Large left transverse process of fifth lumbar vertebra

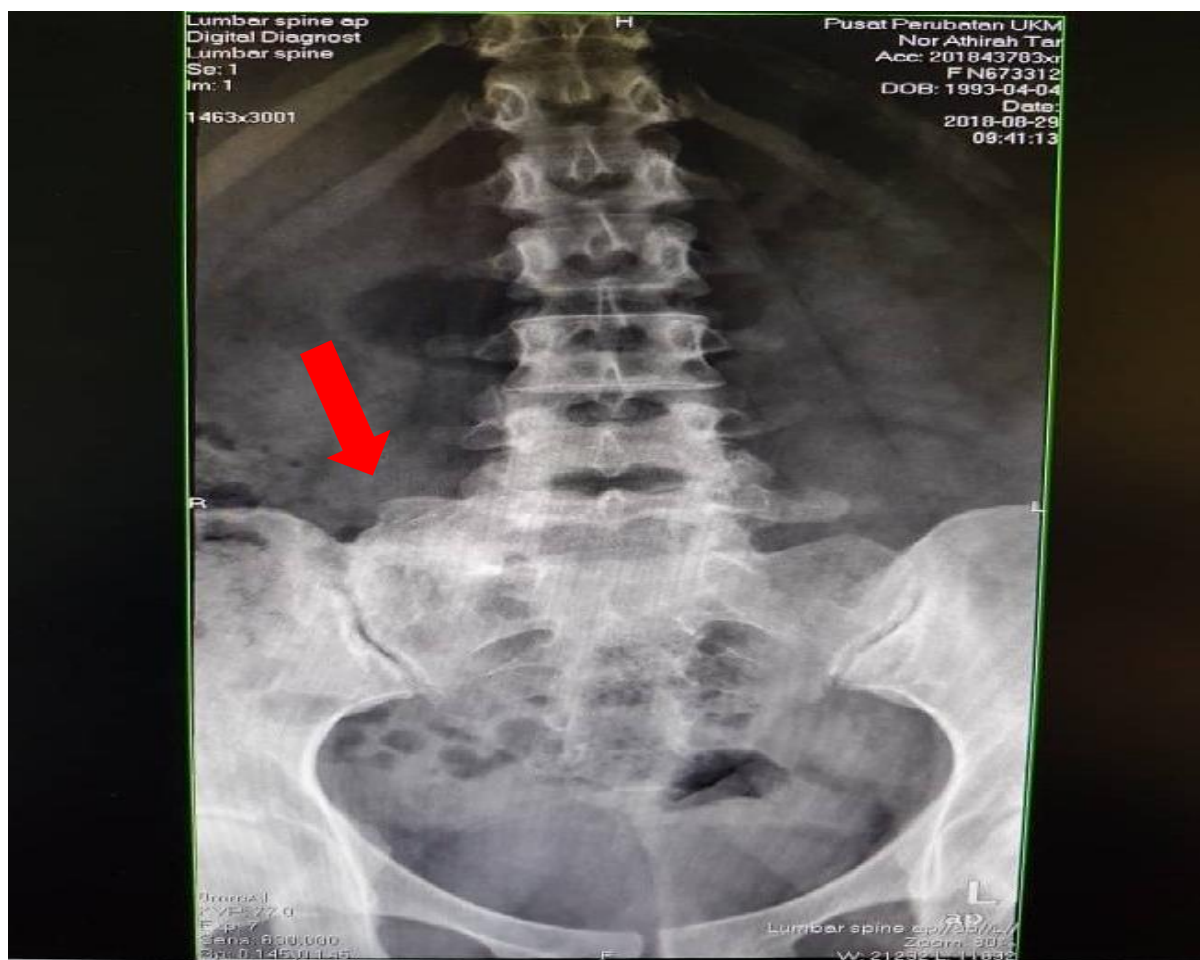57 3) A 30 years old male presented right LBP of mechanical characteristics of long evolution.

58 It increases with the trunk flexion and occasionally radiates to the right lower limb until the

59 knee. Her Oswestry score was 40% indicating moderate disability. The rest of the exploration

60 is normal. The simple X-ray of the spine shows an alteration in the LSTV with a sacral

61 lumbarization and pronounced right transverse processes of L5 (Figure 3).

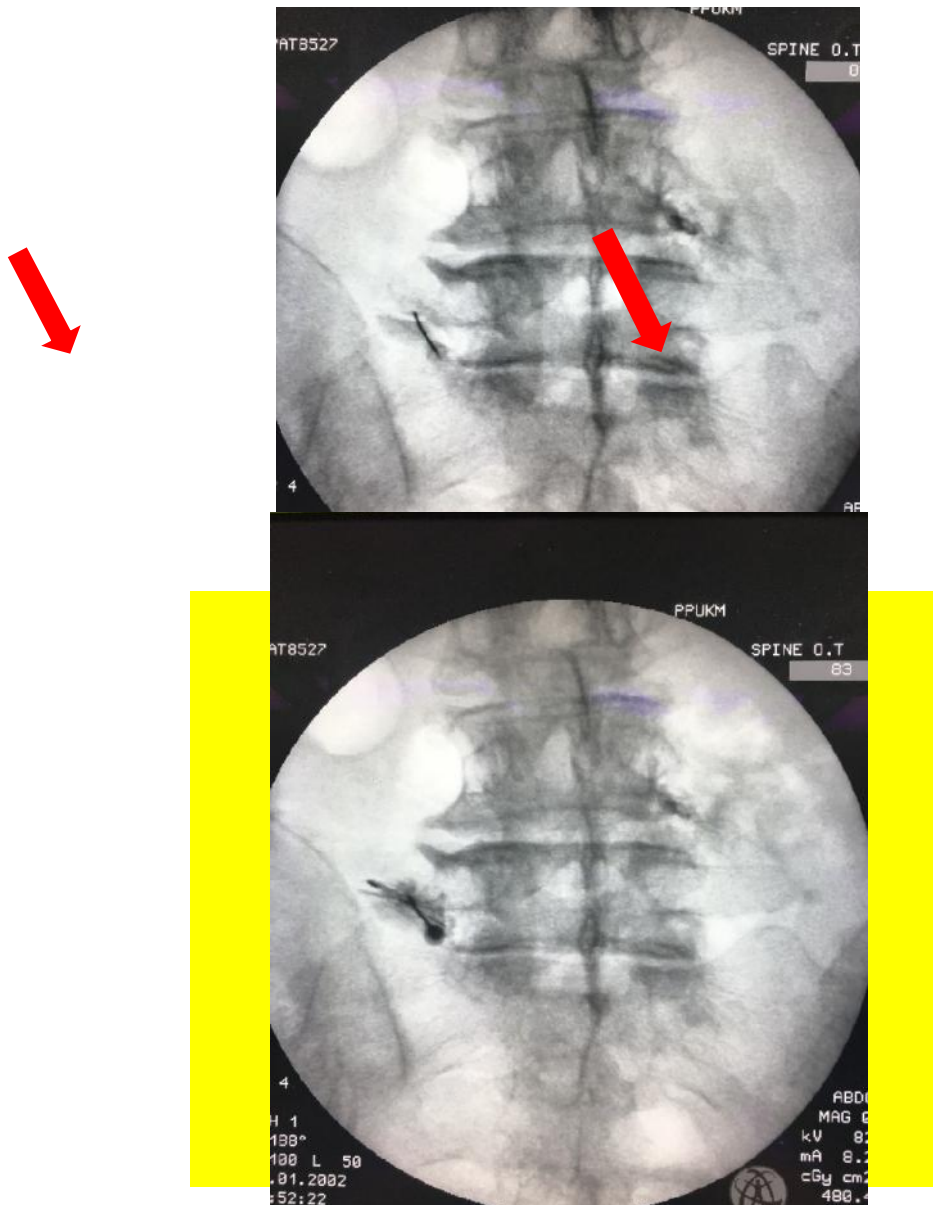


62

63 *Figure 3. Right large lumbosacral transitional vertebra with sacral lumbarization*

64

65 All three patient's clinical examination and radiographs were consistent with the articulation
 66 between the traverse process and ilium as a possible source of pain, we decided to inject local
 67 anaesthetic and corticosteroid into the transverse process—ilium articulation region. We used
 68 a 3-1/2 inch 22-gauge spinal needle inserted into the articulation between the transverse
 69 process and ilium guided by c-arm fluoroscopy, 0.5 mL of Iohexol 240 mg/ml contrast dye
 70 was injected once the needle tip was felt and slip into the joint with evidence of arthrogram
 71 and superior spread is seen (Figure 4). A solution containing 1 ml of ropivacaine 0.75% and
 72 40 mg of triamcinolone acetate was injected on the affected side. During first month of
 73 follow-up in our clinic, the patient's VAS decreased from 6/10 to 3/10 and their Oswestry
 74 score decreased from 40% to 20%. All patients had no symptoms after 6 months of follow up.



75

76

77 *Figure 4. Showed spinal needle inserted and contrast dye injected into the articulation*
 78 *between the transverse process and ilium of right L5TV guided by image intensifier*

79

80

Discussion

81 The aetiology of pain in symptomatic cases of Bertolotti's syndrome (BS) is unknown and
 82 the association of BS with low back pain (LBP) is unclear¹. A possible aetiology for pain
 83 includes the articulation of the transverse process and ilium and resulting degenerative
 84 changes. Secondly, the fused transitional vertebrae may result in instability above the level of
 85 the fusion and third explanation may be because BS is not associated with back pain at all¹
 86 while Wigh et al⁸ and Castellvi et al⁶ found that in patients with back pain and sciatica, the
 87 transitional vertebra had a prevalence of 21% and 30% respectively. Quinlan et al. reported a
 88 higher incidence of low back pain in the younger patient population with BS as all the cases
 89 we reported are young patients⁷. Elster et al. found that the incidence of degenerative disc
 90 disease and spinal stenosis was nearly nine times higher in the level adjacent to the to the

91 transitional vertebrae, suggesting that there may be abnormal biomechanical stress above the
92 fusion⁹.

93 Therapeutic options for symptomatic cases of Bertolotti's syndrome include conservative
94 management and surgery¹⁵. To date, there is no agreement as to the best method of treatment
95 for BS patients. However, we are discussing regarding intraarticular steroid injection as a
96 treatment of choice for our patients as they refused any surgical intervention after failed
97 conservative management such as pain relief medications and physiotherapy.

98
99 There are few literatures were reviewed regarding intraarticular steroid injection for BS.
100 Marks et al. prospectively followed a cohort of ten patients with BS on X-ray⁵. Eight patients
101 had immediate total relief of pain and one patient had total pain relief within the first week
102 after steroid injection. Three patients reported adequate partial relief of pain after periods of
103 six months and one patient remained pain free two years after the intervention. A study by
104 Avimadje et al., twelve patients with LSTV reported same-side LBP or buttock-pain¹⁰. Seven
105 of eight patients improved or had no symptoms after six months to two years after injection.
106 Jain et al. prospectively reported twenty patients with BS and two patients were treated with
107 steroid injections after a diagnostic block in the LSTV was preformed however none of the
108 patients experienced pain relief at the end of the 6-month study period¹¹.

109
110 Some of the studies describing treatment with steroid injections^{11,12} were case reports^{3,12,13} or
111 studies, where the patients refused surgery after selective nerve root block^{12,14}. Unfortunately,
112 there was no follow-up. Two cases have been reported on patients with LSTV articulation in
113 the exit-zone of the root foramen causing impingement of the L5 nerve root^{12,14}. Both
114 received a selective nerve root block with steroid and local anaesthetics, which caused
115 immediate pain relief. The patients had no radiculopathy for two months and a repeat nerve
116 root block was performed¹⁴. The study does not mention any subsequent clinical outcome⁴.

117
118

119 **Conclusion**

120

121 The association between an BS and LBP is still controversial despite a high prevalence and
122 high incidence in younger age group³. The literature regarding the local administered steroid
123 injection and surgical management is very sparse and very few studies have investigated the
124 treatment of BS⁴. Our cases suggest that a simple steroid injection into the articulation
125 between the transverse process and ilium may offer a simple initial diagnostic and therapeutic
126 in the management of symptomatic BS. However further studies with larger sample sizes and
127 longer follow-up periods are warranted for the clinical guidance in this type of treatment.

128
129

130
131

132

133 **References**

134

135 1. Ricardo Vallejo (2009). Bertolotti's Syndrome: A Case Report. Pain Practice, Volume
136 9, Issue 2, 2009 152–154.

- 137 2. Paraskevas G, Tzaveas A, Koutras G, Natsis K (2009). Lumbosacral transitional
138 vertebra causing Bertolotti's syndrome: a case report and review of the literature.
139 Cases J 2, 8320.
- 140 3. Santavirta S, Tallroth K, Ylinen P, Suoranta H (1993). Surgical treatment of
141 Bertolotti's syndrome. Follow-up of 16 patients. Arch Orthop Trauma Surg 112, 82–
142 87.
- 143 4. Holm, E. K., Büniger, C., & Foldager, C. B. (2017). Symptomatic lumbosacral
144 transitional vertebra: a review of the current literature and clinical outcomes following
145 steroid injection or surgical intervention. SICOT-J, 3, 71.
- 146 5. Marks RC, Thulbourne T (1991). Infiltration of anomalous lumbosacral articulations.
147 Steroid and anesthetic injections in 10 back-pain patients. Acta Orthop Scand 62,
148 139–141.
- 149 6. Castellvi AE, Goldstein LA, Chan DP (1984). Lumbosacral transitional vertebrae and
150 their relationship with lumbar extradural defects. Spine (Phila Pa 1976) 9, 493–495.
- 151 7. Quinlan JF, Duke D, Eustace S (2006). Bertolotti's syndrome. A cause of back pain in
152 young people. J Bone Jt Surg Br 88, 1183–1186.
- 153 8. Wigh RE, Anthony HF: Transitional lumbosacral discs: probability of herniation.
154 Spine
155 1981, 6:168-171.
- 156 9. Elster AD: Bertolotti's syndrome revisited. Transitional vertebrae of the lumbar spine.
157 Spine 1989, 14:1373-1377.
- 158 10. Avimadje M, Goupille P, Jeannou J, et al. (1999). Can an anomalous lumbo-sacral or
159 lumbo-iliac articulation causes low back pain? A retrospective study of 12 cases. Rev
160 rhum (Engl Ed) 66, 35–39.
- 161 11. Jain A, Agarwal A, Jain S, Shamsbery C (2013) Bertolotti syndrome: a diagnostic and
162 management dilemma for pain physicians. Korean J Pain 26, 368–373.
- 163 12. Mitra R, Carlisle M (2009) Bertolotti's syndrome: a case report. Pain Pract 9, 152–154.
- 164 13. Mercader Rodriguez B, Sanchez RF, Domenech Abellan E, et al. (2015) Bertolotti
165 syndrome: a little known cause of low-back pain in childhood. J Pediatr 166, 202.
- 166 14. Weber J, Ernestus RI (2010) Transitional lumbosacral segment with unilateral transverse
167 process anomaly (Castellvi type 2A) resulting in extraforaminal impingement of the
168 spinal nerve: a pathoanatomical study of four specimens and report of two clinical
169 cases. Neurosurg Rev 34, 143–150.
- 170 15. Bertolotti M (1917). Contributo alla conoscenza dei vizi di differenziazione regionale
171 del rachide con speciale riguardo all assimilazione sacrale della v. lombare. Radiol
172 Med 4, 113–144.
- 173
174
175