

ESTHETIC CONSIDERATIONS WHEN RESTORING SINGLE MAXILLARY CENTRAL  
INCISOR.

ABSTRACT:

The aim of this article is to illustrate the esthetic rehabilitation of a discolored maxillary central incisor according to dominance principle based on establishing ideal proportions.

The factors that can affect the esthetic value of a dental supported crown in the esthetic zone are also discussed.

These parameters include abutment color, ceramic thickness, the opacity of luting agent and gingival contours.

It describes a clinical situation of restoring a discolored maxillary central incisor using an all ceramic crown. The patient presented with hidden smile and was asking for improvement of her appearance. Clinical examination showed discrepancy between central incisors.

The treatment plan included crown lengthening followed by Lithium Disilicate Ceramic crown. The opacity of the material was selected according to the abutment discoloration.

An IPS Natural Die Material shade guide was also used. The restoration was bonded using a resin material.

Finally, Pink/white esthetic score PES/WES was applied to evaluate the esthetic outcome.

KEY WORDS:

Maxillary central incisor, Esthetics, Glass ceramics, Luting agent, Abutment teeth color.

## 1-INTRODUCTION

Restoring maxillary central incisor is a challenging task for prosthodontists because its morphological features are closely correlated with facial proportions and they present influential factors in esthetic perception.

Williams et al demonstrated that the tooth shape is determined by facial form. [1]

Whereas, many other studies have found no correlation between facial outline and preferred tooth shape. [2] The central incisor should be the most dominant tooth displayed during the smile. Several tools have been suggested for assessing its dominance such as shape, size, shade, incisal edge position and proportions. They constitute starting points for esthetic management of maxillary central incisor. [3, 4]

In fact, the width of a maxillary central incisor is expected to be proportional to its length which determines the width/Length ratio.

According to literature, it was evaluated to be between 75 % and 78%. [5]

Recent studies demonstrated similarities between professionals and non-professionals regarding the dominance of central incisor in dental esthetic perception. [6]

They, both, don't accept any reduction in an average central incisor length. However, a reduction of the width of lateral incisor about 0.5 mm can be unperceived. [5]

According to Spear & Kokich, establishing correct proportions of a central incisor depends also on achieving ideal gingival levels especially when gingival contours are altered.

In the same context, assessing the papilla level relatively to the overall crown length of maxillary central incisor is also considered as an important criterion.

It is in fact an important step in the process of establishing a correct position of maxillary anterior teeth [7].

Dark abutments may negatively affect the esthetic value of a translucent ceramic crown conducting to a discoloration of the restoration in the cervical area .

Material selection depends, so, on the degree of abutment color.

With translucent Ceramics , the final esthetic result is, according to recent studies , interplaying between multiple parameters including ceramic thickness , substrate shade and luting agent color. [8]

For correct restoration color match, clinician needs to have basic knowledge of light science. He is, also, considered to be the responsible for creating a less confusing communication with the laboratory via some tools such as graphics, shade mapping cards, esthetic checklists and shade guide. [9]

Using reliable indices for objective esthetic evaluation is a fundamental step in order to monitor the results over time. Various indices such as pink/white esthetic score (PES/WES) were proposed.

According to literature, this score is recommended to both soft and hard tissues evaluation in implant supported restorations.[10]

PES was introduced by Fürhauser et al. [11]

The PES index involved the following five variables: mesial papilla, distal papilla, the level and curvature of the facial mucosa, root convexity, and soft-tissue color and texture at the facial side of the implant. For mesial and distal papilla, a score of 2 (Complete), 1 (Incomplete), and 0 (Absent) were assigned.

For the remaining three PES parameters, a score of 2 (no discrepancy), 1 (minor discrepancy), and 0 (major discrepancy) were assigned. The highest possible score would be 10 and the threshold of clinical acceptability was set at 6. [12]

WES was based on the five following parameters: general tooth form, outline and volume of the clinical crown, color including the assessment of hue and value, surface texture, translucency, and characterization. A score of 2 was given if there was no discrepancy; score 1 for minor discrepancies; and score 0 for any major discrepancy observed. A maximum total WES was 10 and the threshold of clinical acceptance was set at a score of 6. [12]

It's validity for natural tooth was discussed recently by authors. [13]

## 2- CASE REPORT

This clinical presentation is dealing with the rehabilitation of a discolored central incisor.

It concerns a 23 year old female patient with a chief complaint of poor esthetics.

She was bothered by the discrepancy between maxillary central incisors.

Intra oral examination revealed a resin composite restoration on the concerned tooth with discolored margins.

The patient presents a convex profile with parallel commissural and mid-pupillary lines.

No harmonious smile lines with squared teeth form and size discrepancies were noticed.

Photographs were taken using NIKON D7100 Camera.

Periodontal probing revealed a thick gingival biotype; with gingival thickness of 02 mm and a sulcus depth of 2 mm.

Altered gingival contours, leading to inadequate Width –to-height ratio and discrepancy between the two central incisors, were also detected.(figure1)

Radiological examination showed an adequate canal root treatment.(figure2)

The treatment procedure started by a periodontal treatment consisting on periodontal scaling; followed then by esthetic crown lengthening and Lithium Disilicate Ceramic crown.

Shade selection was performed before any procedure to avoid dehydration of the tooth.

A color mapping card was performed referring to the right central incisor.

The tooth was prepared for all ceramic crown with internal rounded shoulder at sub gingival level edges with no sharp angles.(figure3)

The abutment tooth shade was, then, determined using the IPS Natural Die Material shade guide (Ivoclar Vivadent ref#597090).

Firstly, a handmade provisional restoration, with precisely fitting and highly polished margins was performed using resin material (Texton SS WHITE by prima dental group).

Crown lengthening was performed.

Then, a second indirect provisional restoration was manufactured by CAD-CAM technique (CEREC system) using PMMA ( methymethacrylate based resin ) with higher mechanical properties . It gives the technician sufficient time to fabricate the ceramic crown.

Final restoration was, then, performed using Lithium Disilicate Ceramic material (IPS e.max ®CAD - Ivoclar Vivadent ref#626391) ; high translucency block was used (HT A1/I12 ).

An esthetic try in of the crown before crown staining and glazing allows verification of the crown morphology and color. At this stage, the incisal edge position, the midline, the axial inclination, the gingival margins and the papilla level should be verified [9]. (figure4)

The crown was bonded using a dual cured resin luting cement (Variolink N. Ivoclar Vivadent, ref #642981 AN) according to the protocol described by Magne and Cascione.[14]

First, the internal surface of the crown was thoroughly rinsed with water then cleaned with alcohol. Second, the ceramic restoration was etched during 60 to 90 sec using HFI 9% acid (IPS Ceramic Etching Gel- Ivoclar Vivadent AG ref#6322 548). Then fresh silane was applied for 60 seconds.

On the other side, the tooth surface was etched with 36% orthophosphoric acid.

Finally, bonding agent was applied. All cement should be removed before polymerization and any remaining residue should be removed with a sickle scaler or a #12 scalpel blade.

The final restoration was assessed using *White/ Pink esthetic score (WES/PES)*.

Significant differences between initial and final scores of the *WES/PES* were evident.

The white score (WES) was increased from (1/10) to (8/10); however, the Pink score (PES) was improved from (5 /10) to (9/10).(figure5)

This improvement is noticed on gingival health showing no more inflammation and better architecture compared to the initial situation.

When it comes to white assessment, the final situation shows a natural mimicry in terms of shape, color, and texture and incisal edge position.

### 3- DISCUSSION

Restoring single central incisor, according to the principle of dominance, remains a challenge for prosthodontists. In fact, central incisor can have three main shapes square, tapered or triangular. [1]

According to a recent systematic review, which was dealing with lay preferences for dentogingival esthetic parameters, it has been shown that tapered incisors are the most attractive in both male and female. [15]

The incisal edge position of the central incisor is of great importance in esthetic perception; it should be parallel to mid-pupillary line. As mentioned by authors, vertical asymmetries as small as 0.6 mm were perceived as unacceptable according to Brazilian population. [16]

Esthetic crown lengthening contributes not only to getting the correct width –To Length ratio, but also to the correction of gingival asymmetries. [5]

The management of the provisional restoration after esthetic crown lengthening is a fundamental step. Its role is essential for the healing process. It, also, allows the verification of the shape of the tooth.

Precisely fitting and highly polished margins are strongly recommended. [17] They should be placed prior to crown lengthening and then modified according to new gingival levels. [18]

As mentioned by authors, soft tissue healing is mostly completed after 8 weeks. Definitive restoration can be, then, successfully placed within 8–12 weeks.

The impression step should be delayed until a subsequent appointment once soft tissue health has been re-established. [17]

Ceramic material selection is depending on the abutment shade. High translucent materials are generally rejected in favor of opacious one in case of discolored underlying substrate. [18]

As recommended by authors, a ceramic thickness of 02 mm is sufficient to mitigate the dark aspect of underlying substrate. [19]

Characterization of central incisor surface texture is as important as matching the shade. Indeed, it is important to consider anatomical shape characterizing the buccal surface of the central.

Three ridges and two concavities were overall created to mimic a natural micro-geography aspect. [9]

Resin cement may cause visually unacceptable color changes with thin ceramic restorations; the color change effect decreases when the ceramic thickness increases.

It concerns especially laminate veneers of 0.5 to 1 mm of thickness.[19]

According to literature *WES /PES* index was essentially recommended to evaluate supported implant restorations, but its rightness for objective evaluation of single tooth crown has been confirmed by recent studies.[13]

### 3-CONCLUSION

Restoring single central incisor, according to the principle of dominance, remains a challenge for prosthodontists; for that some guidelines regarding the shade, proportions, size should be respected.

The underlying tooth structure has primary effect on the appearance of the definitive ceramic restoration. To eliminate this undesirable effect factors such as ceramic thickness, ceramic shade and cement color should be considered.

Shade selection, ceramic material selection and appropriate communication with the laboratory technician are combined factors for success.

#### 4- REFERENCES

1. Williams JL. A new classification of human tooth forms with reference to a new system of artificial teeth. *Dent Cosmos*. 1914; 56:627–628.
2. Kurt M , Anderson RG et al. Tooth shape preferences in an esthetic smile. *Am J Orthod Dentofacial Orthop* 2005; 128:458-65.
3. Hasanreisoglu U, Berksun S, Aras K et al . An analysis of maxillary anterior teeth: facial and dental proportions. *J Prosthet Dent* 2005; 94:530-8.
4. Petropoulou A, Pappa E, Pelekanos S. Esthetic considerations when replacing missing maxillary incisors with implants: a clinical report. *J Prosthet Dent* 2013; 109:140-144.
5. Snow SR. Esthetic smile analysis of anterior tooth width: the golden percentage. *J Esthet Dent*. 1999; 11:177–84.
6. Shetty S, Pitti V, Satish Babu C et al. To evaluate the validity of Recurring Esthetic Dental proportion in natural dentition. *J Conserv Dent* 2011; 14:314-7.
7. Spear FM1, Kokich VG. A Multidisciplinary Approach to Esthetic Dentistry. *Dent Clin N Am* 51 (2007) 487–505 .
8. Yada Chaiyabutr, John C. Kois, Dene LeBeau, and Gary Nunokawa. Effect of abutment tooth color, cement color, and ceramic thickness on the resulting optical color of a CAD/CAM glass-ceramic lithium disilicate reinforced crown. *J Prosthet Dent* 2011; 105:83-90.
9. Mizrahi B. Restoration of a single central incisor with an all-ceramic crown: a case report. *International Dentistry SA* vol.10, no.3.
10. Vidigal GM Jr, Groisman M, Clavijo VG .Evaluation of Pink and White Esthetic Scores for Immediately Placed and Provisionally Restored Implants in the Anterior Maxilla. *Int J Oral Maxillofac Implants*. 2017 May/Jun.
11. Fürhauser R, Florescu D, Benesch T et al. Evaluation of soft tissue around single-tooth implant crowns: the pink esthetic score. *Clin Oral Implants Res* 2005; 16:639–644.



12. Lavigne SE, Krust-Bray KS, Williams KB et al. Effects of subgingival irrigation with chlorhexidine on the periodontal status of patients with HA-coated integral dental implants. *Int J Oral Maxillofac Implants* 1994;9:156–162.
13. Lanza A, Di Francesco F, De Marco G et al. Clinical Application of the PES/WES Index on Natural Teeth: Case Report and Literature Review. *Case Rep Dent*. 2017.
14. Magne, P; Cascione, D. Influence of post-etching cleaning and connecting porcelain on the microtensile bond strength of composite resin to feldspathic porcelain. *The Journal of Prosthetic Dentistry*, (2006)96(5), 354–361.
15. Del Monte S, Afrashtehfar K, Emami E et al. Lay preferences for dentogingival esthetic parameters: A systematic review. *J Prosthetic Dent*. 2017 Dec; 118(6):717-724.
16. Machado AW, Moon W, Gandini LG. Influence of maxillary incisor edge asymmetries on the perception of smile esthetics among orthodontists and laypersons. *American Journal of Orthodontics and Dentofacial Orthopedics* Volume 143, Issue 5, May 2013, Pages 658-664.
17. Fletcher P. Biological rationale of aesthetic crown lengthening using innovative proportion gauges. *International J. Periodontics Restorative Dent*. 2011, 31, 523–532.
18. Calandriello M, Carnevale G, Ricci G. *Parodontologia*. Bologna: Martina Press, 1980.
19. Sedanur Turgut, Bora Bagis. Effect of resin cement and ceramic thickness on final color and laminate veneers: An in vitro study. *Journal of prosthetic dentistry* 2013; 109:179-186.

## CONSENT

As per international standard or university standard, patient's written consent has been collected and preserved by the authors.

## ETHICAL APPROVAL

All the information of participants was kept anonymously and secretly and all the ethical principles were considered.

## ACKNOWLEDGEMENTS

The authors would like to thank colleagues from the department of prosthodontics for their support. A special thank for the laboratory technician who performed the restorations.

## AUTHOR CONTRIBUTIONS

- Ahmed Besroul worked with Nissaf Daouahi on structuring, writing the manuscript; and collecting also the references part.
- Ahmed Besroul and Adel Amor took the photos and carried out the clinical procedure.
- Dalinda Hadyaoui provided the necessary corrections for manuscript.
- Mounir Cherif supervised and provided the necessary materials

## CONFLICTS OF INTEREST

The authors report no conflicts of interest. The authors alone are responsible for the content and the writing of this article.

FIGURES

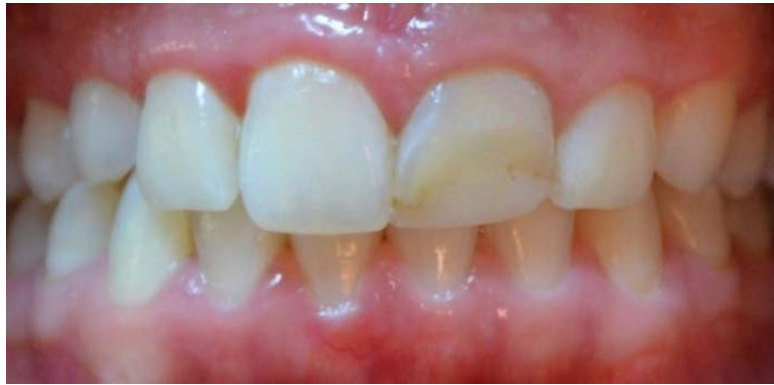

Figure 1: Retracted preoperative full-mouth view showing discolored margins of resin

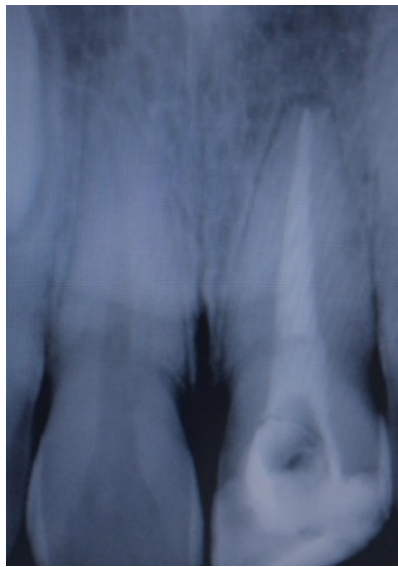
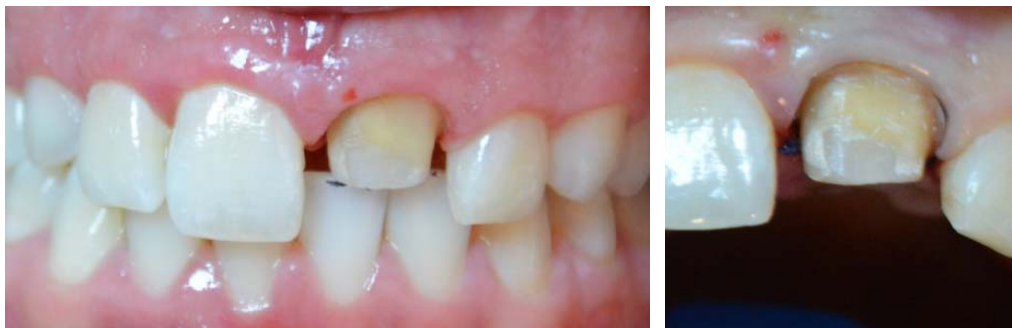
Figure 2: Radiological examination



A

B

Figure 3: Abutment tooth after healing period: tooth preparation

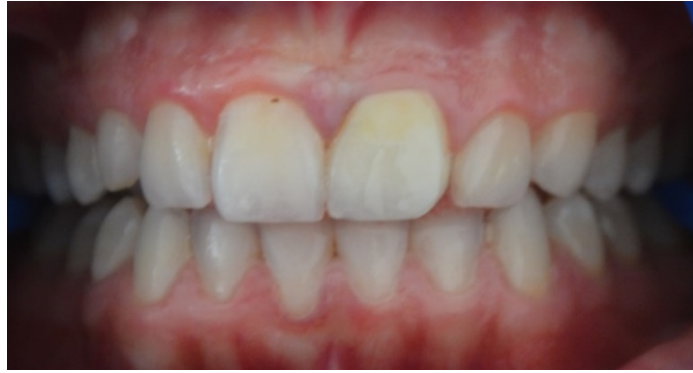

Figure 4: Retracted close-up postoperative view of the maxillary anterior restoration

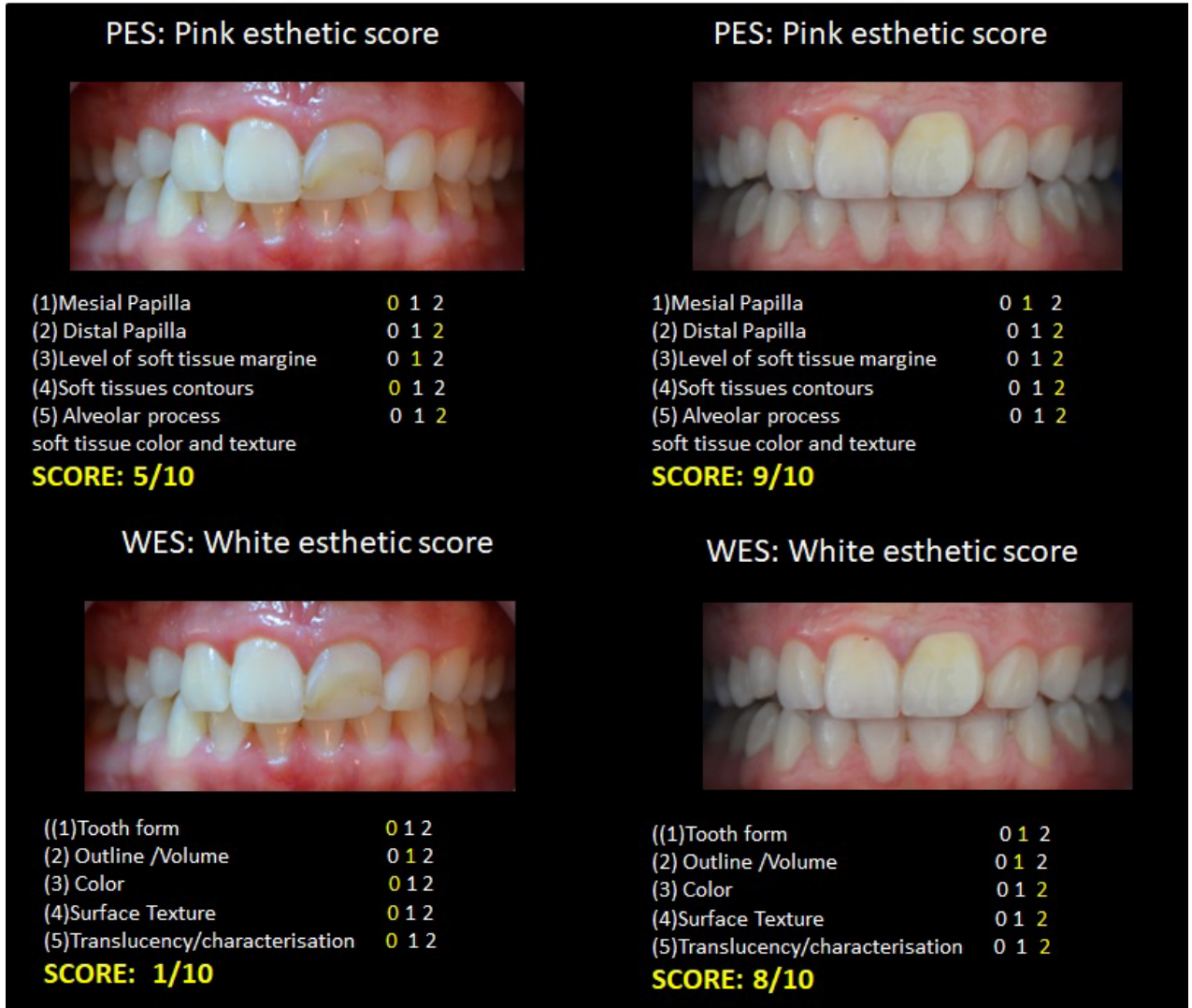


Figure 5 : Initial WES/PES Versus Final WES/PES